



ELSEVIER

Available online at www.sciencedirect.com

SCIENCE @ DIRECT®

Transfusion and Apheresis Science 30 (2004) 139–144

TRANSFUSION
AND APHERESIS
SCIENCE

intl.elsevierhealth.com/journals/tras

Use of autologous fibrin-platelet glue and bone fragments in maxillofacial surgery

Gabriella Giannini ^{a,*}, Valbonesi Mauro ^a, Tel Agostino ^b, Bindi Gianfranco ^b

^a *Department of Immunohematology and Blood Transfusion, San Martino University Hospital,
Largo Rosanna Benzi 10, 16132 Genoa, Italy*

^b *Department of Maxillofacial Surgery, San Martino University Hospital, Largo Rosanna Benzi 10, 16132 Genoa, Italy*

Accepted 30 November 2003

Abstract

The use of autologous cryo-platelet gel and bone fragments in maxillofacial surgery is described. Cryo-platelet gel has been used successfully in 5 patients who underwent surgery for maxillary or mandibular problems. The level of improvement was scored, arbitrarily, from 0 to 4. Very favourable results were seen in our 5 patients. The glue preparation is very easy and inexpensive and the glue creates excellent and stable hemostasis. From a general point of view, we add additional anecdotal evidence supporting the utility of fibrin-platelet glue in terms of reduced infections and length of hospital stay, which suggest the need for well planned and controlled trials to show if there is benefit and when and this treatment modality should be used in maxillofacial surgery.

© 2004 Elsevier Ltd. All rights reserved.

Keywords: Autologous fibrin-platelet glue; Growth factors; Wound healing

1. Introduction

Methods for preparation, in the blood bank, of biological glues are many ranging from preparation of fibrin glue to the preparation of platelet gels. Their use depends mostly on the expected results. The main advantage of fibrin glue is its tensile strength which helps in wound healing and cessation of hemorrhage. Platelet derived glues are

somehow complementary since they have a poor tensile strength but promote tissue regeneration due to their content of growth factors. The many potential uses for fibrin glue in the field of oral and maxillofacial surgery were first set forth in the literature by Matras in 1982 [1]. She described fibrin sealant as a material possessing the qualities of tissue sealing, hemostasis, and promotion of wound healing. In this article and an update in 1985 [2], Matras presented case reports on the use of fibrin glue in microneural and microvascular anastomoses, as a hemostatic agent in soft tissue deficits, as a replacement for suture material in the split thickness skin graft procedure, in the re-approximation of comminuted bone fragments in complicated fractures and in dural closure. The

* Corresponding author. Tel.: +39-010352859/5553928; fax: +39-0105556807.

E-mail address: gabriella.giannini@hsanmartino.liguria.it (G. Giannini).

fibrin sealant developed by Matras is currently marketed in Europe under the trade name of Tisseel (Immuno, Vienna, Austria); it has recently gained FDA approval in the United States but this was delayed because of the earlier reported risk of viral transmission associated with its use. The risk of infectious disease transmission from commercially available fibrin glue systems has led to the development of numerous autologous techniques for preparing this useful material [3,4]. However, these autologous techniques generally require patient interaction with the blood bank at least 3 days before the planned surgery and advanced coordination by the surgeon. Clerical error by the blood bank still places the patients at risk for a potential transfusion reaction or infectious disease complication. Finally, the patient making the donation must meet the blood bank's criteria for weight, hemoglobin concentration, age and general health. The most recently published reports in the oral and maxillofacial surgery literature regarding the use of fibrin glue have been in the area of mandibular reconstruction where Tayapongsak et al. [5,6] have reported success in using the glue as an adhesive carrier for autogenous particulate cancellous bone and marrow in conjunction with both allogeneic cribs and alloplastic trays.

Our blood bank is involved in both the production of cryo-platelet gels and their application during surgery. Results were compared with those of a historical group in terms of infection rate, length of hospital stay (LHOS) and clinical effect.

2. Materials and methods

Our blood bank is involved in a program for collecting platelet and plasma immediately preoperatively for the purpose of producing cryo-platelet glue to be used intraoperatively. Briefly, autologous platelets anticoagulated with ACD-A were collected according to the dry-platelet collection technique employing an Excel apparatus (Dideco Spa Mirandola, Italia), as previously described [7]. From 3.6 to 5×10^{11} platelets were collected in 20–25 ml of plasma, along with 450–

500 ml of autologous plasma which was subsequently used to obtain 40–50 ml of cryoprecipitate. After collection the plasma unit was immediately frozen at -80 °C in a mechanic refrigerator, and the frozen plasma was then put at 4 °C for 18–24 h for spontaneous thawing. Cryodepleted plasma was removed and the residual cryoprecipitate dissolved in 40–50 ml of plasma and frozen for subsequent use. The apheresis platelet concentrate was frozen at -80 °C, without any further manipulation.

Immediately before the end of the surgery, 10 ml of platelet concentrate is mixed with 10 ml of cryoprecipitate, 3 ml of Botropase (Ravizza Farmaceutici Spa Milano, Italia) and 3 ml of calcium gluconate in a sterile Petri plastic dish. The Petri dish content is evenly mixed to get a gel-like material in 2–4 min.

The cryo-platelet gel was used in maxillofacial surgery to cover osteotomy and interplantation of bone blocks from the iliac crest or from the skull. At each operation 5–6 fragments of cancellous bone were obtained and used immediately. Particular attention was paid to the presence of red bone marrow because of the theoretical presence of mesenchymal progenitor cells.

Between December 2002 and September 2003, 5 patients, after an appropriate informed consent, underwent surgery for maxillary or mandibular problems.

Our case-list includes 3 male and 2 female patients with a mean age of 46.6 years (range 30–65 years). The diagnosis was severe maxillary bone atrophy for 3 patients, maxillary skeletal deformity (progenia) for 1 patients and right hemimandibular pathological fracture for the last patient (Table 1).

Table 1
Patient data

Patient	Sex/age	Diagnosis
1	F/65	Severe maxillary bone atrophy
2	M/30	Maxillary skeletal deformity (progenia)
3	M/42	Right hemimandibular pathological fracture
4	M/45	Severe maxillary bone atrophy
5	F/51	Severe maxillary bone atrophy

3. Case reports and results

The results obtained after surgery for three out of our 5 patients are documented photographically (Fig. 1). Patients 4 and 5 are not documented since the results were the same as for case 1.

Case 1

Diagnosis: severe maxillary bone atrophy.

Intervention: maxillary bone autologous reconstruction with iliac crest block insertion after Le Fort osteotomy I and complete maxillary mobilization (Fig. 1A–D).

Case 2

Diagnosis: maxillary skeletal deformity (progenia).

Intervention: upper maxillary advancement and mandibular setback (Fig. 2A–D).

Case 3

Diagnosis: right hemimandibular pathological fracture.

Intervention: horizontal maxillary branch reconstruction with bone implants from skull (calvaria) (Fig. 3A–E).

Comparing the results in these 5 patients with the results observed in a group of 20 consecutive comparable patients undergoing surgery for the same indications a reduction in LHOS of 3 days was seen along with the absence of infection which, in contrast, were seen in patients in the control group. The level of improvement was scored, on an arbitrary bases, from 0 (no improvement) to 4 (complete healing) (Table 2).

4. Discussion

The process of wound healing is complex and involves a series of interactions between platelets and macrophages. In the first 2 days following

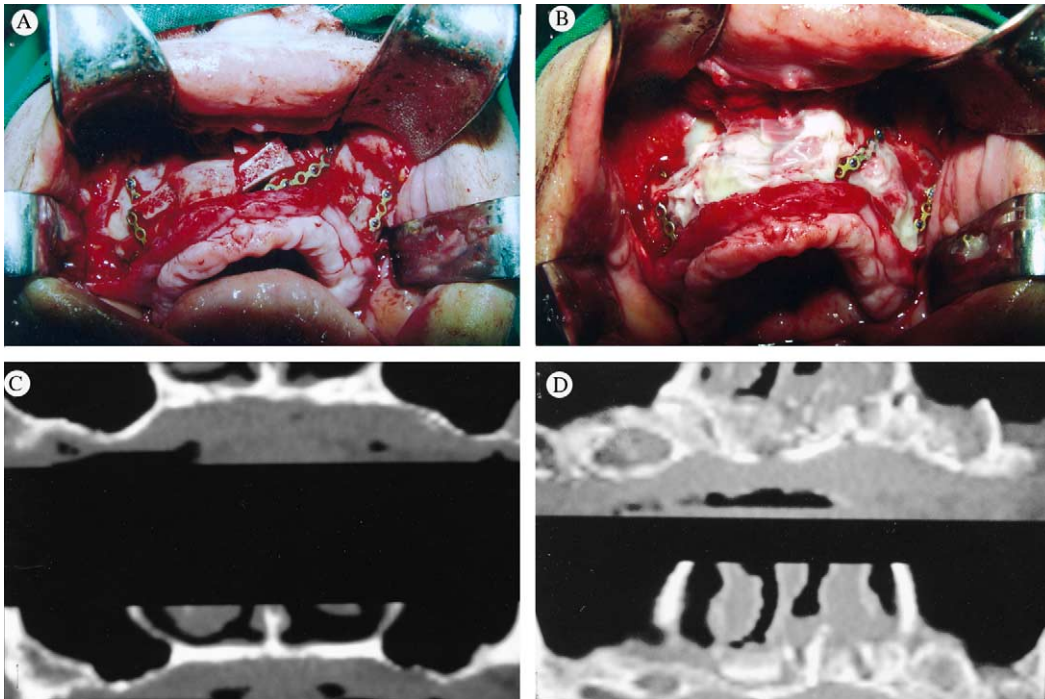


Fig. 1. (A) Le Fort upper maxillary osteotomy I with drawdown and interplantation of bone blocks from the iliac crest. (B) Wide cover of bone reconstruction through fibrin-platelet glue, before suture. (C) Automated tomography with overview projection: note the complete absence of the alveolar process of the maxilla. (D) Post-surgical automated tomography: whole maxillary volume bone reconstruction.

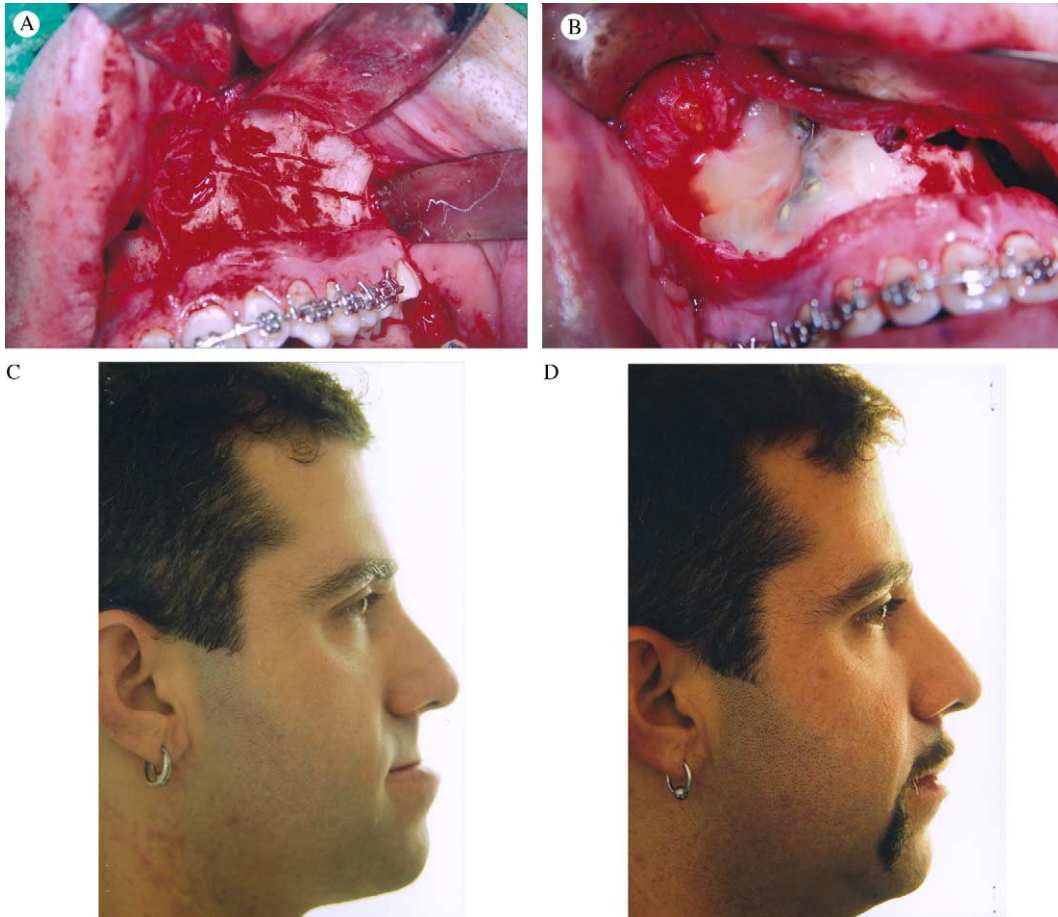


Fig. 2. (A) Upper maxillary osteotomy with putting forward. (B) Cover of osteotomy and method of fixation (plate in titanium) with a large quantity of fibrin-platelet glue. (C) Patient's profile before intervention. (D) Patient's profile after intervention.

injury, growth factors are produced and released by platelets. Thereafter, this function is taken over by macrophages. Within the α -granules of the human platelet are multiple growth factors that are released when platelets are activated and degranulated. These include platelet derived growth factor (PDGF), transforming growth factor (TGF- β), fibroblast growth factor (FGF), epidermal growth factor (EGF), platelet derived angiogenesis factor and β -thromboglobulin. PDGF seems to be the first growth factor present in the wound, and it initiates connective tissue healing, including bone regeneration and repair. The most important specific activities of PDGF include mitogenesis (an increase in the cell populations of healing cells),

angiogenesis (endothelial mitoses into functioning capillaries), and macrophage activation (debridement of the wound site and a second-phase source of growth factors for continued repair and bone regeneration). TGF, when released by platelet degranulation or actively by macrophages, acts as a paracrine growth factor (i.e., growth factors secreted by one cell exerting their effect on an adjacent second cell), affecting mainly fibroblasts, marrow stem cells and the preosteoblasts. However, each of these target cells has the ability to synthesize and secrete its own TGF proteins to act on adjacent cells in a paracrine fashion or act on itself as an autocrine growth factor. TGF therefore represents a mechanism for sustaining a long-term

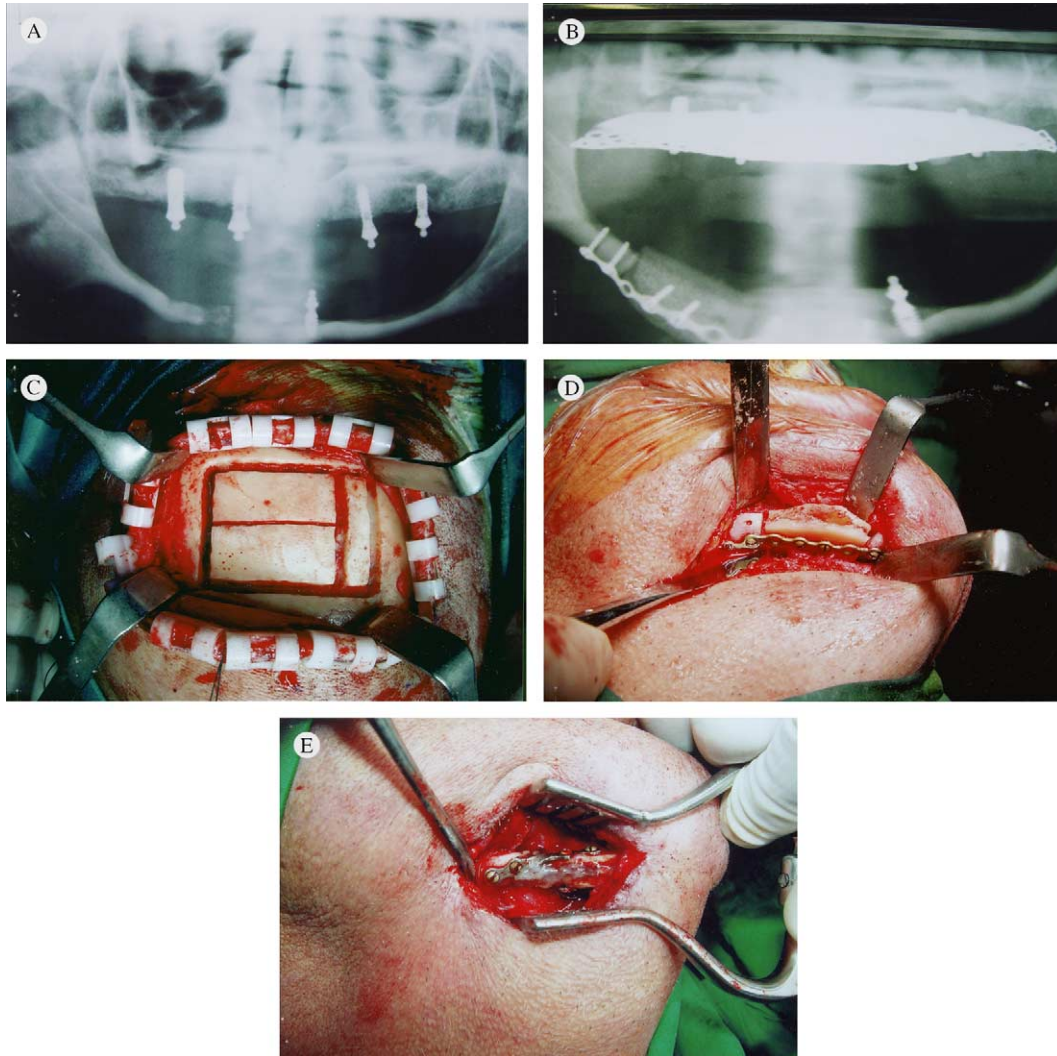


Fig. 3. (A) Orthopantomogram showing right hemimandibular pathological fracture. (B) Orthopantomogram after bone implant reconstruction (calvaria). (C) Spongy-cortical spear from cranial theca (parietal bone). (D) Mandibular reconstruction with bone implants. (E) Cover and fibrin-platelet glue insertion into bone gaps.

Table 2

Results obtained in the 5 patients (LHOS: length of hospital stay)

Pt	LHOS days	Infection Yes/No	Use of antibiotics Yes/No	Result at 30 days	Score 0/4
1	3	No	Yes	Excellent healing of soft tissues	4
2	3	No	Yes	Excellent healing of soft tissues	4
3	3	No	Yes	Excellent healing of soft tissues	4
4	3	No	Yes	Excellent healing of soft tissues	4
5	3	No	Yes	Excellent healing of soft tissues	4

healing and bone regeneration module and may even evolve into a bone-remodelling factor over time. The most important function of TGF seems to be the chemotaxis and mitogenesis of osteoblast precursor; it also has the ability to stimulate osteoblast deposition of collagen matrix of wound healing and of bone. In our study, a purified autologous platelet releasate has been prepared by stimulating human platelets to release the contents of their α -granules. Use of a platelet releasate in wound healing has advantages. The growth factors that are released are identical to and in the same proportion as the growth factors normally brought to the wound by the platelets. Preparation of a platelet releasate is relatively easy and inexpensive because the platelets can be harvested from peripheral blood. They readily release the contents of their α -granules when stimulated with Ca gluconate and batroxobin. The use of autologous material eliminates the risk of transmission of viral disease; the formula for fibrin-platelet glue preparation is simple and standardized.

No study was carried out on platelet quality or viability and the platelets were frozen without any cryoprotectant since, in reality, their function after thawing is the provision of phospholipid membranes along with the provision of preformed growth factors for incorporation into the gel.

In the Department of Maxillofacial Surgery, we have successfully used this technique in conjunction with ablative surgical procedures of the maxillofacial region, and for maxillary and mandibular reconstruction. Also, we have adopted the practice of using cryo-platelet glue to obtain hemostasis after anterior iliac bone harvest. The use of particulate cancellous bone and marrow (PCBM) grafts to reconstruct severe maxillary bone atrophy is a well-established technique with proven success [8]. The importance of adequately particulating, condensing, and adapting the bone graft material has been shown [9]. Even with complete and adequate dissection of the recipient bed, the PCBM graft can be displaced through soft tissue manip-

ulation during closure. By applying autologous platelet gel to the PCBM, adequate initial consolidation of the graft is obtained. This consolidation allows for manipulation of the flap without displacement of the bone graft. Besides the obvious mechanical benefits of using autologous cryo-platelet glue with PCBM grafts, physiologic benefits may also be assumed. The introduction of fibrin and the release of the numerous growth factors should enhance the healing potential of the autologous bone graft perhaps stimulating the stem cells which are potentially present. Nonetheless, from a clinical point of view, based on comparison with the results obtained in these or comparable patients seen at our facility who were treated conventionally, we are convinced of the absolute utility of fibrin-platelet glue in terms of reduced infections and length of hospital stay.

References

- [1] Matras H. The use of fibrin glue in oral and maxillofacial surgery. *J Oral Maxillofac Surg* 1982;40:617.
- [2] Matras H. Fibrin seal: the state of the art. *J Oral Maxillofac Surg* 1985;43:605.
- [3] Saltz R, Sierra D, Feldman D, et al. Experimental and clinical applications of fibrin glue. *Plast Reconstr Surg* 1991; 88:1016.
- [4] Hartman AR, Galankis DK, Honig MP, et al. Autologous whole plasma fibrin gel: intraoperative procurement. *Arch Surg* 1992;127:357.
- [5] Tayapongsak P, O'Brien DA, Monteiro CB, et al. Autologous fibrin adhesive in mandibular reconstruction with particulate cancellous bone and marrow. *J Oral Maxillofac Surg* 1994;52:161.
- [6] Tayapongsak P, Pijut LJ, Scheffer RB. Inferior border cribs in mandibular reconstruction. *Oral Surg Med Oral Pathol Oral Radiol Endod* 1995;79:10.
- [7] Valbonesi M, Bruni R, et al. Dry platelets with the Dideco Excel apparatus. *Transfus Sci* 1999;20:101–6.
- [8] Boyne PJ. Autogenous cancellous bone and marrow transplants. *Clin Orthop* 1970;73:199.
- [9] Marx RE. The science and art of reconstructing the jaws and temporomandibular joints. In: Bell WH, editor. *Modern practice in orthognathic and reconstructive surgery*. Philadelphia, PA: Saunders; 1992. p. 1448–531.